WHITE PAPER

SmartXide²

Ulcer with Exposed Bone in an Amputation Stump Treated with an Innovative Pulsed CO_2 Laser Technique: a Case Study

DEKA

Innate Ability

Ulcer with Exposed Bone in an Amputation Stump Treated with an Innovative Pulsed CO_2 Laser Technique: a Case Study

Carlo Mirabella, M.D. - Department of Cellular Therapy and Transfusion Medicine.
Careggi University Hospital. Florence, Italy.

Introduction

Treating ulcers with exposed bone is more critical than the treatment of shallower lesions that do not involve the bone surfaces. Such treatments are very demanding due to the high risk of infection and the difficulty inherent in developing the granulation tissue needed for wound healing. Below we present our experiment with a 73-year-old patient suffering from an ulcer with exposed bone in the amputation stump of the 1st toe on the left foot. The patient was treated for two and a half years with advanced dressings and also using a high-power pulsed CO_2 laser (SmartXide² – DEKA, Italy). The laser was initially mainly used to debride the ulcers on the amputation stumps. Only at the end of 2007 was a bone-needling technique tested, in an attempt to heal a wound, which had been open for over two years.

Case History

September 2005: Following post-thrombotic acute ischaemia of the patient's left foot, she reported necrosis of the 1st, 2nd and 5th toes. The 1st toe was amputated before the patient was taken into care by our clinic (Figure 1). The patient was revascularized and dressings were applied to encourage the open wound to close, awaiting amputation of the other two necrotic toes.

After revascularization, the perfusion of the microcirculation was assessed (Figure 2). This showed a good flowmetric response to local heating, with a 478.05% increase (max 102.82 PU). The baseline laser-doppler blood flow was rather above the norm (40 PU), with a reduction of the veno-arteriolar reflex (VAR) by -55.59%. Increase in TcpO2 (TcpO2 = 50mmHg), though slight (+6.99%).

Figure 1. Initial conditions of the left foot with the 1st toe already amputated, and necrosis of the 2nd and 5th toes.

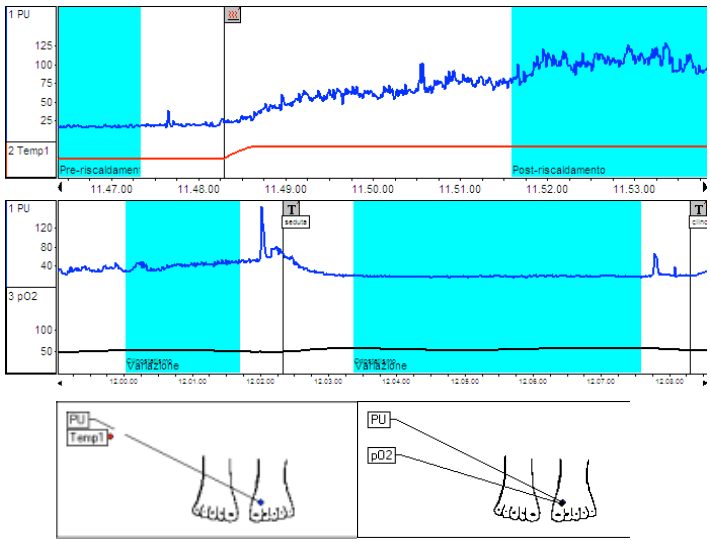

Figure 2. Results of the laser-doppler and TcpO2 tests.

In June 2006, the amputation of the 2nd and 5th toes on the left foot was also performed (Figure 3).

Figure 3. Patient after amputation of the 2nd and 5th toes on the left foot.

In July 2006, beginning with an initial phase of CO_2 laser treatments to debride the amputation wounds. After 4 months of treatment, the lesions have almost completely closed. The problem of the bone exposed at the point of amputation of the 1st toe, though, remains (Figure 4).

Figure 4. The picture shows the amputation stump of the 2nd toe which has almost completely closed and re-epithelialized, while the stump of the 1st toe continues to show the exposed bone with no trace of granulation tissue and small skin grafts "resting" against the bone. A red patch in the image is due to a fungal infection (treated with specific therapy).

From March to December 2007, two attempts were made to graft with regenerative dermal matrix directly on the bone to try to create the conditions for a complete closure of the open wound. Both attempts failed without leading to any improvement with regard to exposure of the bone surfaces (Figures 5 and 6). One first attempt was made in May 2006, without any success, before amputation of 2nd and 5th toes.

Figure 5. (**A**) Second attempt to graft with regenerative dermal matrix. (**B**) Wound conditions after two months. The exposed bone is still noticeable.

As no appreciable results were obtained, it was decided to act more deeply, using the CO_2 laser at high power and in pulsed mode, to perforate the bone until blood came out of the periosteum (Figure 7A). The rationale of this new experimental technique derives from the fact that the blood that comes out is rich in multipotent cells, which can provide growth factors capable of promoting the wound healing process. At this point, only after having caused blood to flow out of the periosteum, the graft was applied for the fourth time with regenerative dermal matrix (Figure 7B).

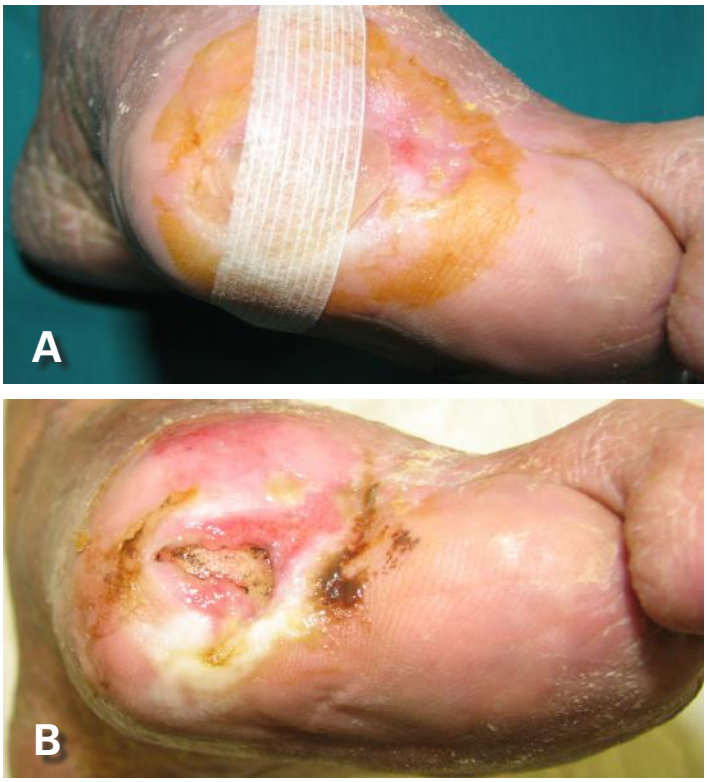

Figure 6. (**A**) Third attempt to graft with regenerative dermal matrix. (**B**) Wound conditions after about a month without any significant improvement. Small, dark marks can be seen on the bone surface caused by an attempt to stimulate the regeneration process by removing the surface of the cortical bone using a laser.

Figure 8. (**A**) The image shows a clear improvement in the lesion 19 days after the "laser bone needling" procedure with the CO_2 laser. It can be seen that the bone surface is entirely covered with granulation tissue. (**B**) Follow-up 4 months and a half after laser treatment with the fully re-epithelialized wound.

Figure 7. (**A**) The image shows the amputation stump after the "laser bone needling" procedure that caused blood to flow out of the periosteum. (**B**) Fourth application of the graft with regenerative dermal matrix.

This fourth attempt solved the situation. Nineteen days after the laser treatment, the bone surface was completely covered by granulation tissue (Figure 8A). Four and a half months after the "bone needling" procedure, the lesion has completely re-epithelialized (Figure 8B).

The procedure described above is a possible solution in cases where the exposure of the bone surface prevents the formation of granulation tissue, which is a necessary component of the healing process. A CO_2 laser beam, of appropriate intensity and pulse shape, can be used to perforate the bone through to the periosteum. This enables blood rich in pluripotent stem cells to reach the ulcer surface, thus starting up the healing process.

This pilot project marked the first case in which this approach was used in a stump which had previously failed heal for over two years. After this first case, further experiments were successfully performed with other patients suffering from ulcers or wounds with exposed bone with different aetiology. This case study is a preliminary evaluation of this new technique, and its effectiveness should be investigated and tested through a randomized study with a control group.

Follow us on

DEKA
Innate Ability

www.dekalaser.com

DEKA M.E.L.A. s.r.l.
Via Baldanzese,17 - 50041 Calenzano (FI) - Italy
Tel. +39 055 8874942 - Fax +39 055 8832884

El.En. Group

© DEKA 007-0124-10-020 Rev.1.0